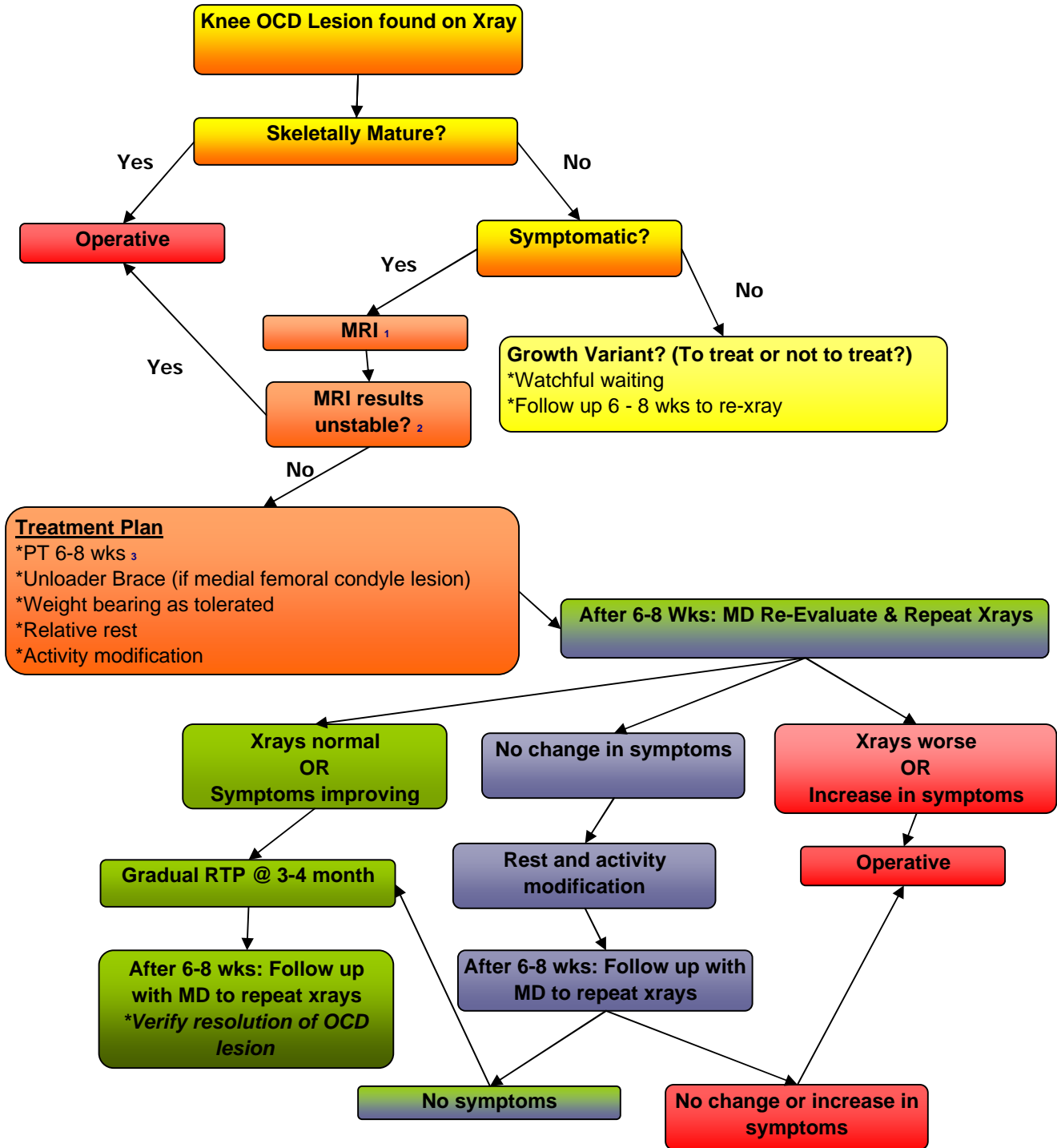


Knee OCD Lesion



1 - **MRI Order:** sagittal + coronal T₂ ; sagittal + coronal fat sat.

2 - **MRI is operative / unstable if:**

- * breach in cartilage
- * loose body
- * increase fluid between mother bone and progeny bone

3 - **PT:** nonimpact; no resisted closed chain exercises; no heavy load